Oral mucosal lesions

Macule:
Flat discolored area (NO depression or elevation)

Papule:
Small circumscribed raised lesion, < 0.5 -1 cm in diameter

Plaque:
Broad flat raised lesion

Nodule:
Large circumscribed raised lesion, > 0.5 -1 cm in diameter

Ulcer:
Depressed area results from break of mucous membrane, mostly covered with yellow membrane.

Papillary:
Raised lesion Showing finger-like surface projections

Sessile

Pedunculated

Vesicle

Pustule

Bulla

Figure 13–2 Primary herpetic gingivostomatitis in a child. Painful gingival (*A*) and tongue (*B*) lesions had been present for 4 days with associated fever and malaise. This was a first-time attack. In 10 days with only supportive care, the patient was asymptomatic and well.

Acute Herpetic Gingivostomatitis: Widespread yellowish mucosal ulcerations.

Acute Herpetic Gingivostomatitis. Painful, enlarged, and erythematous facial gingiva. Note erosions of the free gingival margin.

Figure 13–3 Primary herpetic gingivostomatitis in an adolescent. *A*, Intraoral and labial ulcers of 5 days duration associated with sudden onset, fever, pain, and lymphadenopathy. There were no other medical findings or associated causative factors. *B*, One week later, the patient was essentially without signs or symptoms; and at the end of 2 weeks from the onset, she was completely healed. Treatment included acyclovir for 5 days, fluids, and anti-inflammatory-antipyretic analgesics.

Recurrent herpes labialis

Multiple fluid-filled vesicles on the lip vermilion.

Herpes Labialis. Multiple sites of recurrent herpetic infection secondary to spread of viral fluid over cracked lips.

Intraoral Recurrent Herpetic Infection. Multiple coalescing ulcerations on the hard palate.

Herpetic whitlow

Figure 13–6 Characteristic herpetic whitlow contracted by contact between this patient's finger cuticle and herpes simplex virus type 1-infected saliva.

- Microscopically, intraepithelial vesicles containing exudate, inflammatory cells, and characteristic virus-infected epithelial cells are seen. Virus-infected keratinocytes contain one or more nuclear inclusions.

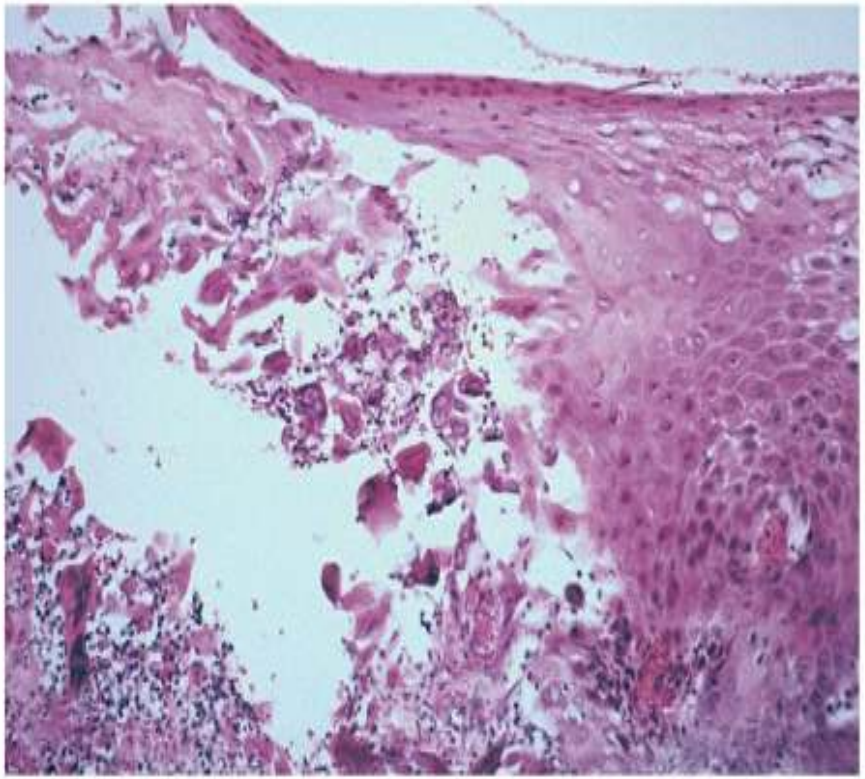

• **Fig. 7-13 Herpes Simplex.** Intraepithelial vesicle demonstrating acantholytic and virally altered epithelial cells.

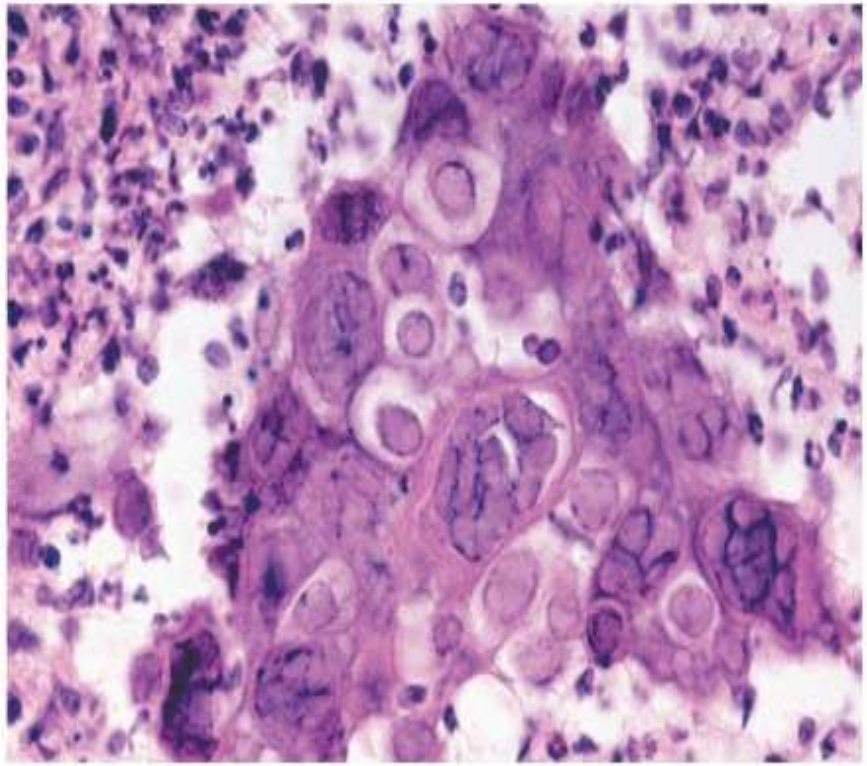

• **Fig. 7-12 Herpes Simplex.** Altered epithelial cells exhibiting ballooning degeneration, margination of chromatin, and multinucleation.

primary varicella zoster (chicken pox) Fever, chills, malaise, and headache may accompany a diffuse rash that involves primarily the trunk and head and neck.

Herpes Zoster. Numerous crusting facial vesicles that extend to the midline.

Herpes Zoster. Numerous white opaque vesicles on the right buccal mucosa of the same patient

Herpes zoster involving the mandibular division of the trigeminal nerve. The skin shows recently ruptured,crusted vesicles. The tongue shows a later stage with healing ulcers.

FIGURE 4-7 Facial lesions of herpes zoster involving the second division of trigeminal nerve.

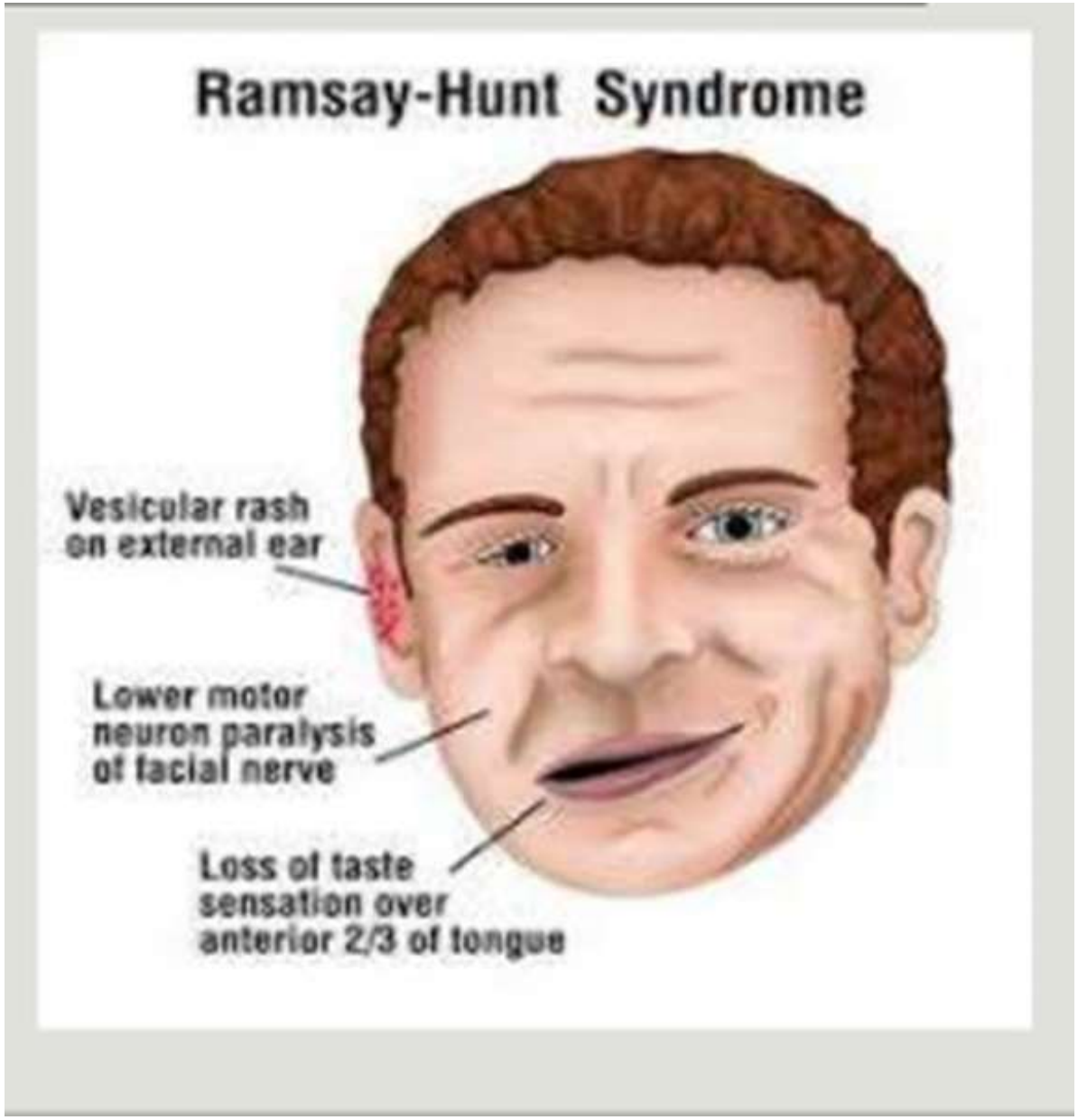
Ramsay-Hunt Syndrome
Vesicular rash on external ear
Lower motor neuron paralysis of facial nerve
Loss of taste sensation over anterior 2/3 of tongue

Herpangina

- acute viral infection caused by Coxsackie type A virus.
- Endemic, typically in summer or early autumn
- Intraorally, a vesicular eruption appears on the soft palate, faucial pillars, and tonsils and persists for 4 to 6 days

Hand-Foot-and-Mouth Disease

- highly contagious viral infection , Coxsackie type A16 or enterovirus 71
- Pain from oral lesions is often the patient's chief complaint.
- Multiple maculopapular lesions, typically on the feet, toes, hands, and fingers

MEASLES

- highly contagious viral infection caused by a member of the **paramyxovirus** family of viruses.
- German measles is a contagious disease that is caused by an unrelated virus of the **togavirus** family.

- In 1 to 2 days, pathognomonic small erythematous macules with white necrotic centers appear in the buccal mucosa, these lesion spots, known as Koplik's spots. Koplik's spots generally precede the skin rash by 1 to 2 days

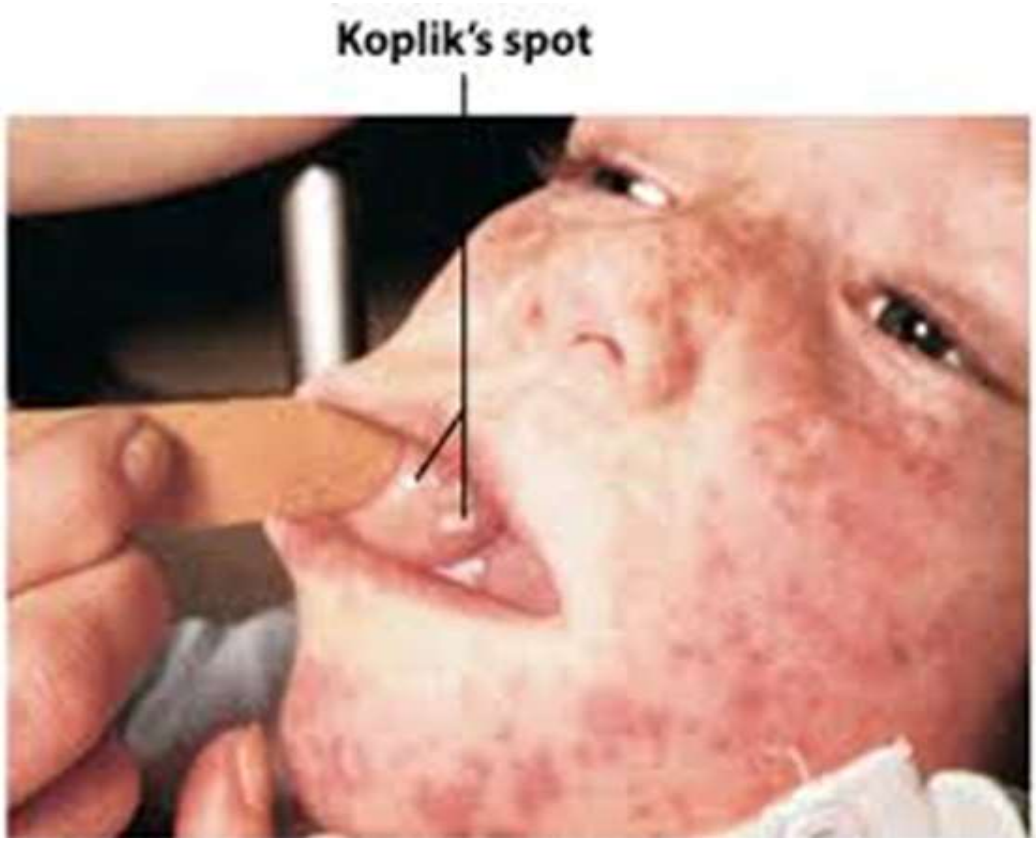

Bacterial infections

Necrotizing Ulcerative Gingivitis

Painful necrosis of the interdental papillae and the gingival margins ,formation of craters covered with a gray pseudomembrane.

NOMA

- also known as cancrum oris and gangrenous stomatitis.
- characterized by a destructive process of the orofacial tissues.

Syphilis

Primary stage:

- The characteristic lesion in the primary stage is the **chancre**
- and clinically presents as a painless ulcer with a smooth surface, raised borders, and an indurated base.

Secondary stage:

• **Fig. 5-9 Mucous Patch of Secondary Syphilis.** Irregular thickened white plaque of the right soft palate.

• **Fig. 5-8 Mucous Patch of Secondary Syphilis.** Circumscribed white plaque on the lower labial mucosa. (Courtesy of Dr. Pete Edmonds.)

• **Fig. 5-10 Condyloma Lata.** Multiple indurated and slightly papillary nodules on the dorsal tongue. (Courtesy of Dr. Karen Novak.)

Tertiary syphilis:

• **Fig. 5-11 Tertiary Syphilis.** Perforation of the hard palate. (Courtesy of Dr. George Blozis.)

• **Fig. 5-12 Hutchinson Incisors of Congenital Syphilis.** Dentition exhibiting crowns tapering toward the incisal edges. (From Halstead

- **Fig. 5-13 Mulberry Molar of Congenital Syphilis.** Maxillary molar demonstrating occlusal surface with numerous globular projections.

Histopathology. spirochetes can be demonstrated in the tissues of various lesions of syphilis using silver stains

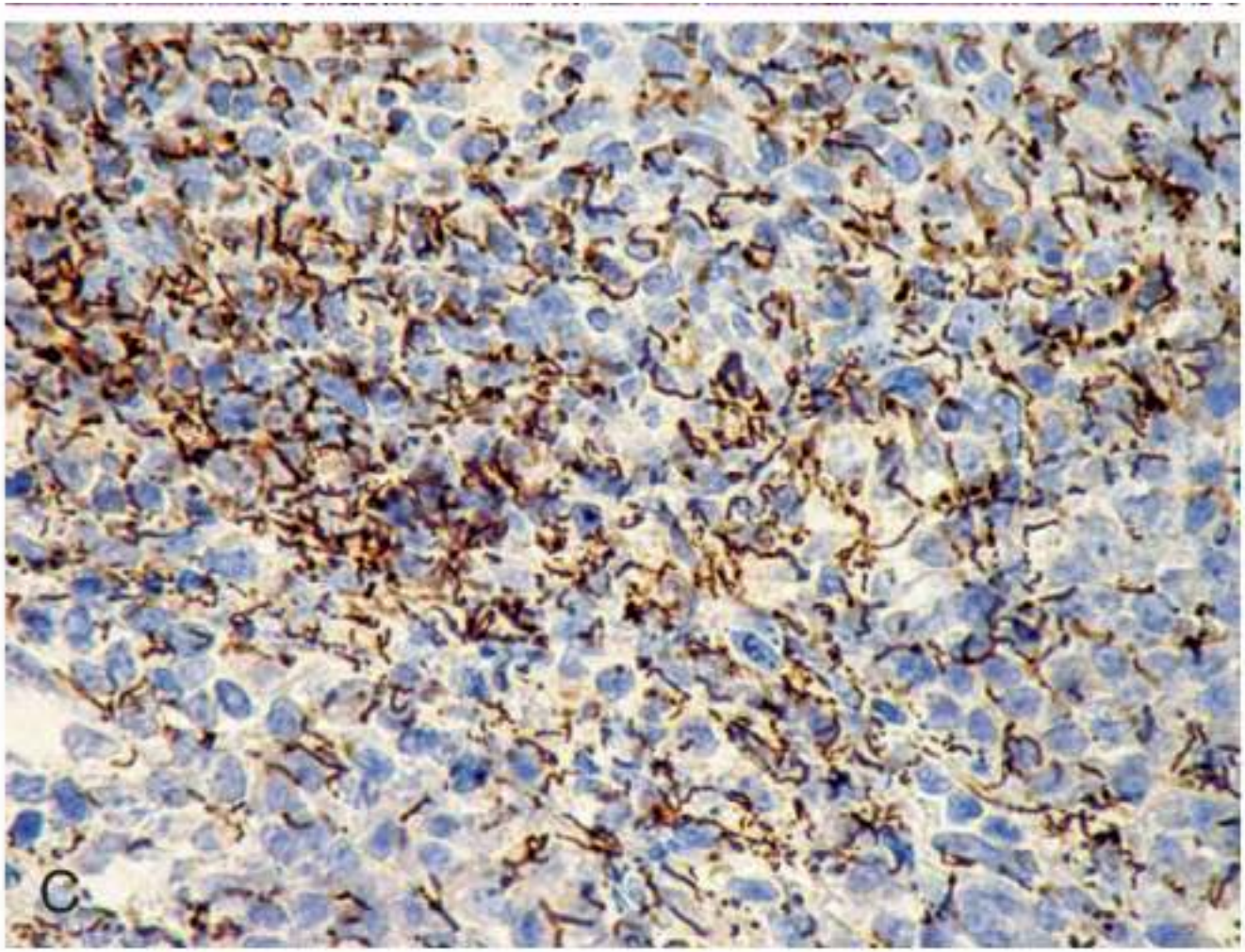

Tuberculosis

Clinically, the ulcer is painless and irregular, with a thin undermined border and a vegetating surface, usually covered by a gray-yellowish exudate. The surrounding tissues are inflamed and indurated

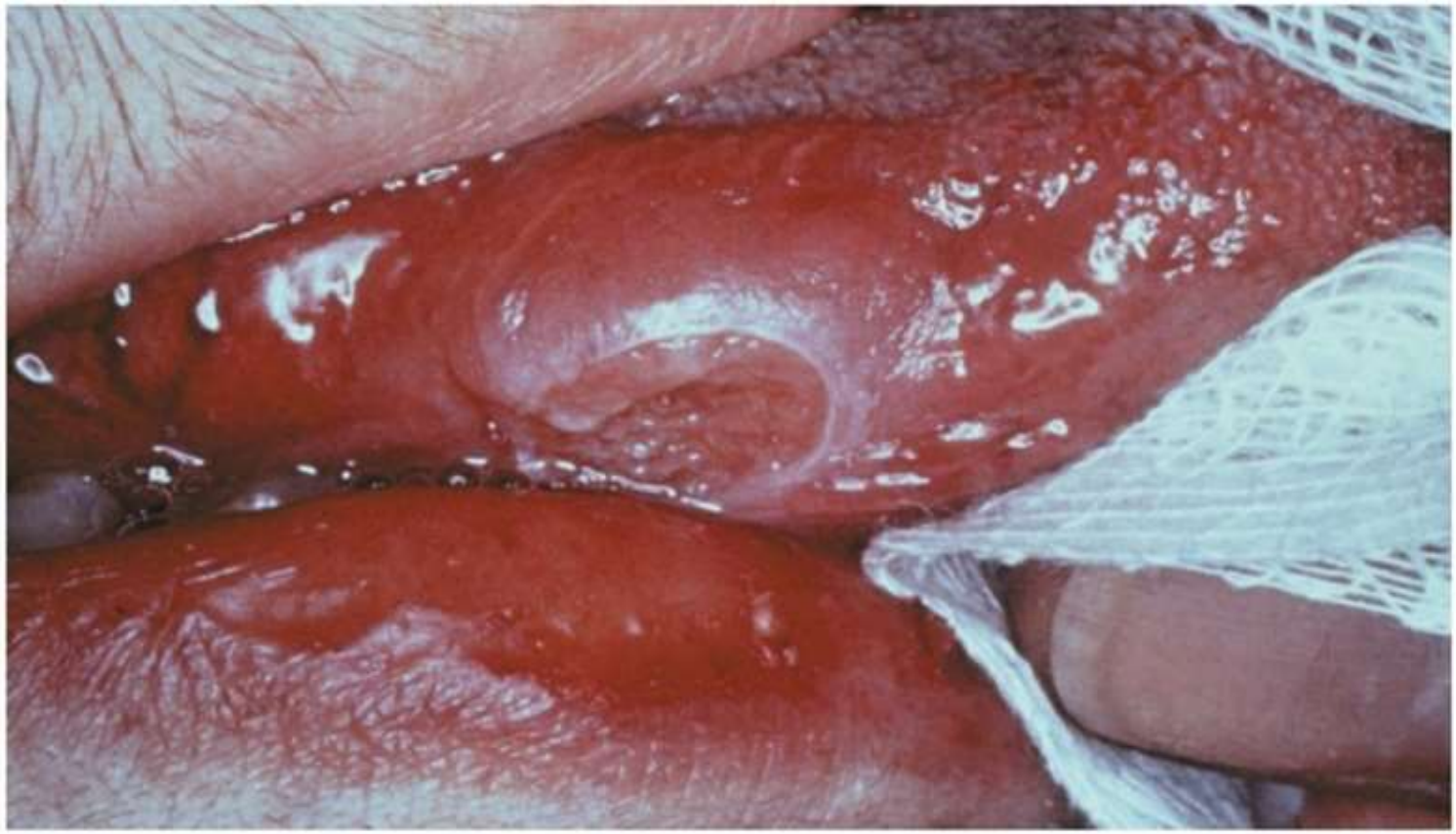

• **Fig. 5-19 Tuberculosis (TB).** Enlargement of numerous cervical lymph nodes. (Courtesy of Dr. George Blozis.)

• **Fig. 5-20 Tuberculosis (TB).** Submandibular fistula secondary to involvement of underlying cervical lymph nodes.

Histopathology

- A granulomatous inflammation, in which granulomas show central caseous necrosis. Focal zones of macrophages become surrounded by lymphocytes and fibroblasts
- Langerhans giant cells, in which nuclei are distributed around the periphery of the cytoplasm.

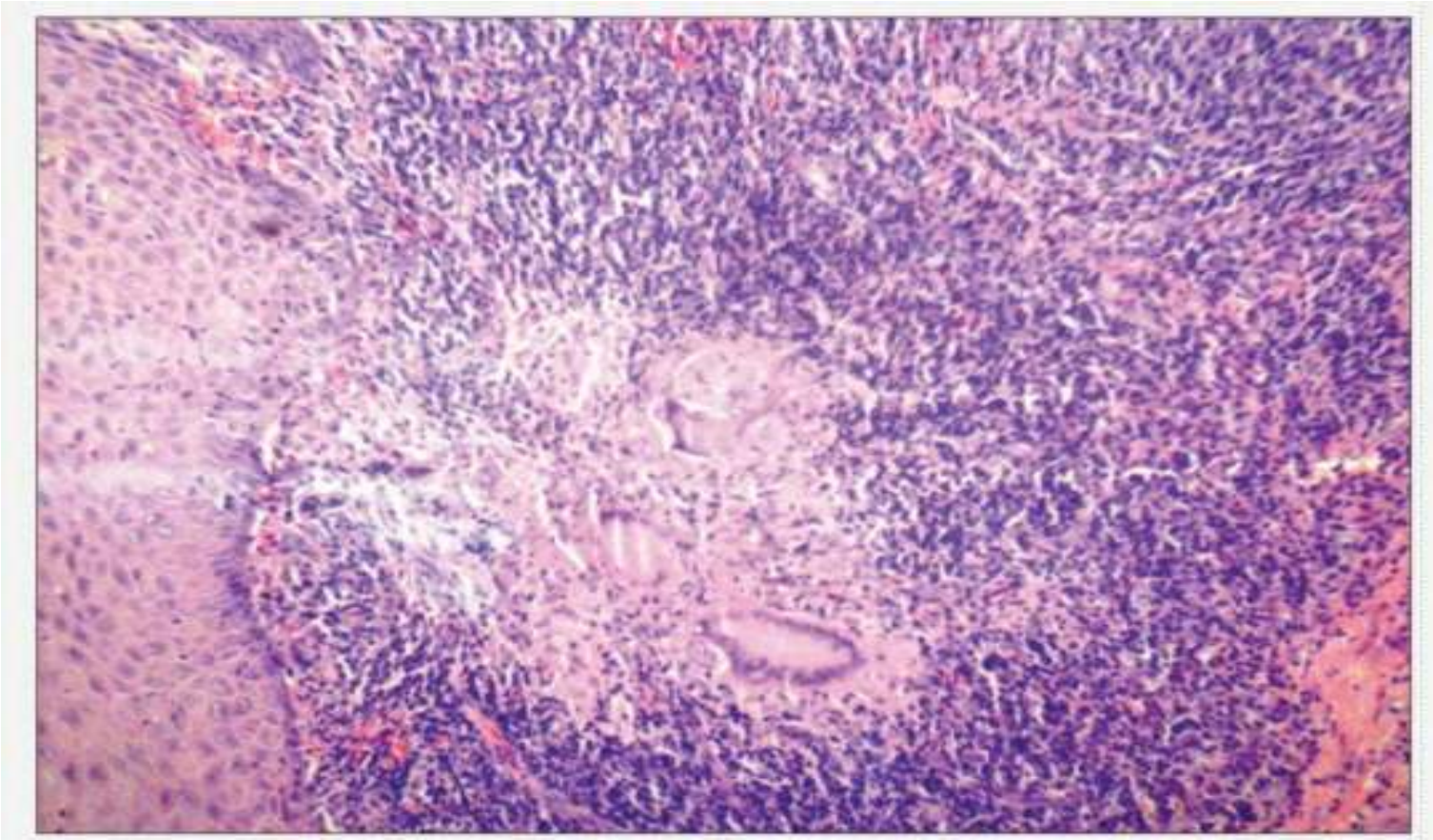

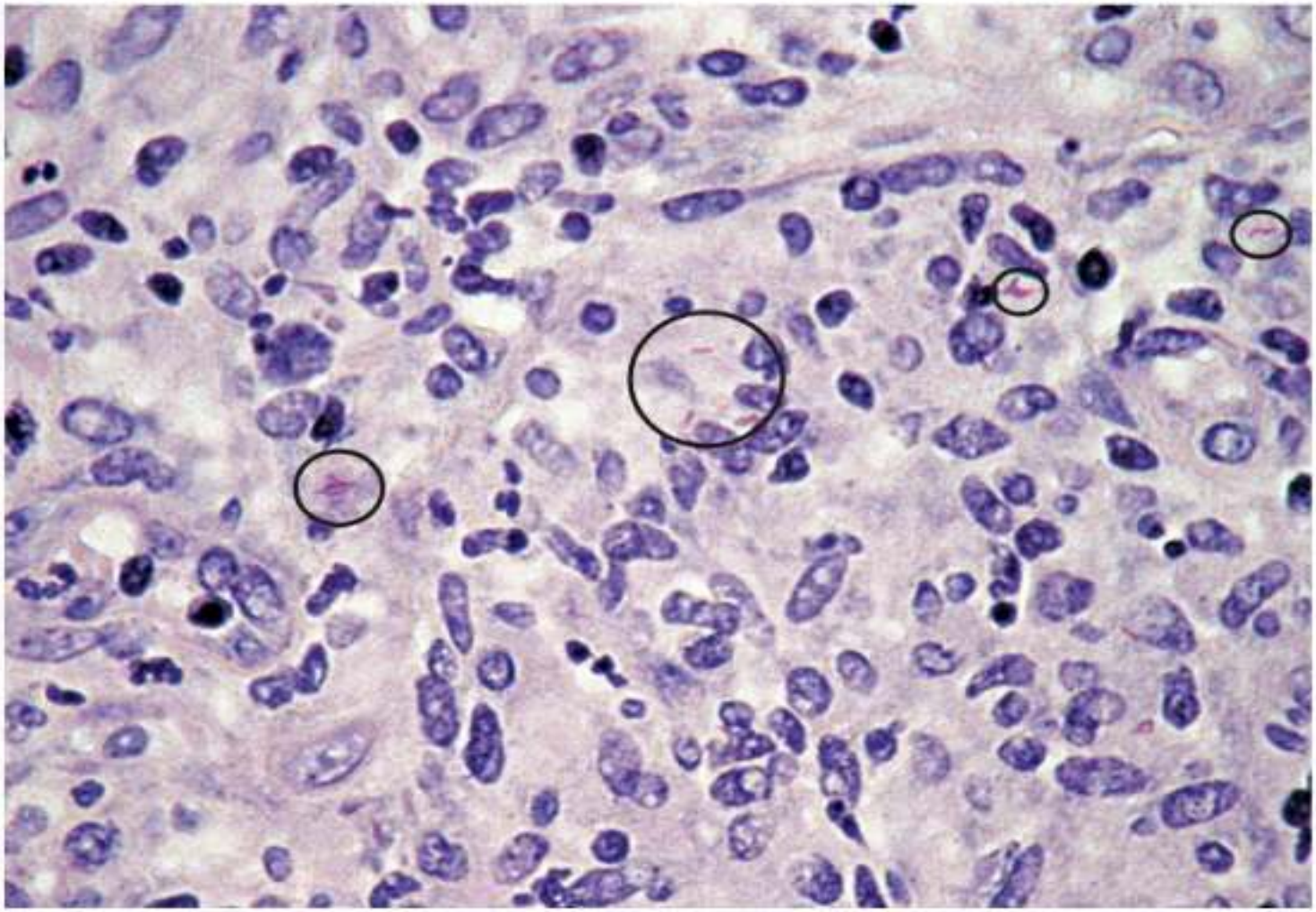

• **Fig. 5-23 Tuberculosis (TB).** Acid-fast stain of specimen depicted in Fig. 5-22 exhibiting scattered mycobacterial organisms presenting as small red rods.

Actinomycosis

- chronic bacterial disease caused by **Actinomyces israelii,** an anaerobic , gram-positive bacterium.
- swelling of the mandible that may simulate a pyogenic infection.
- The lesion may become indurated and eventually may form one or more draining sinuses,

• **Fig. 5-31** **Actinomycosis.** Draining fistula of the right submandibular area.

Histopathology

- A granulomatous inflammatory response with central abscess formation

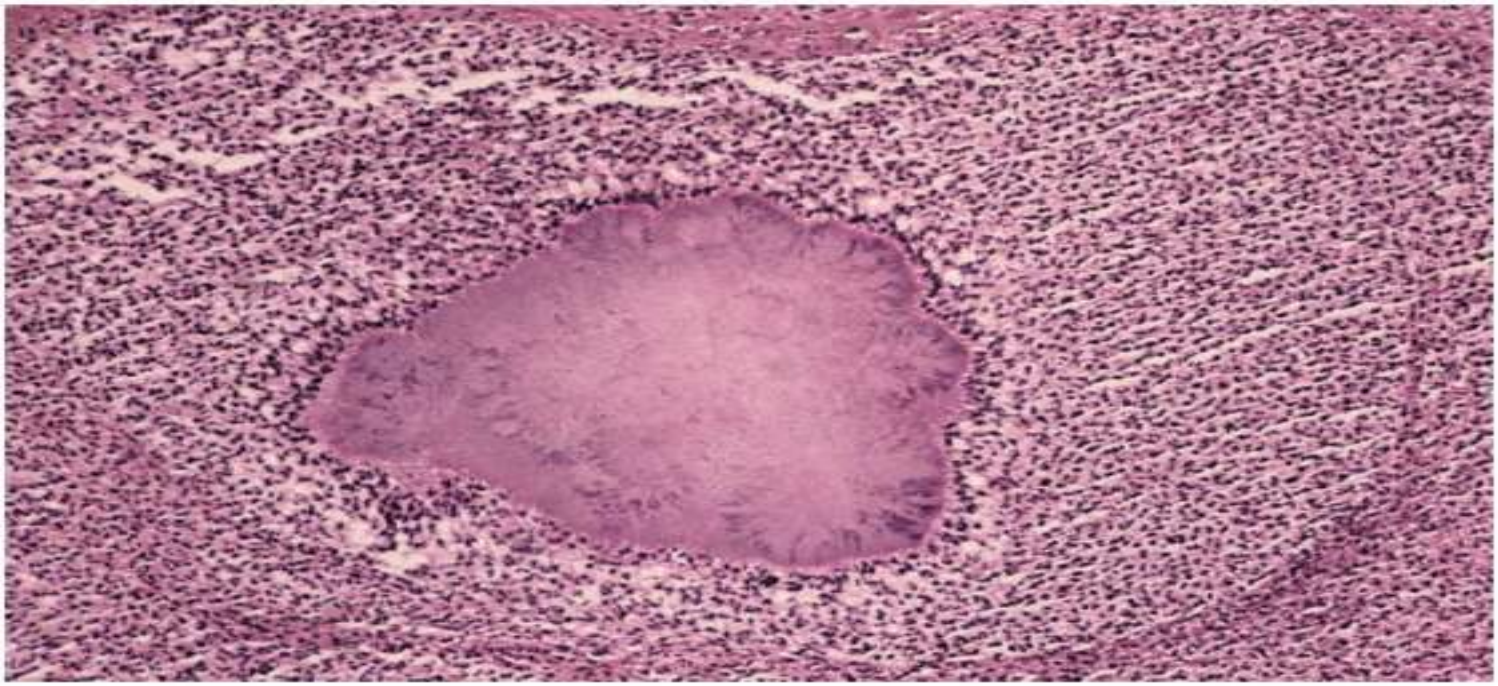

• **Fig. 5-32 Actinomycosis.** Colony of actinomycotic organisms surrounded by polymorphonuclear leukocytes.

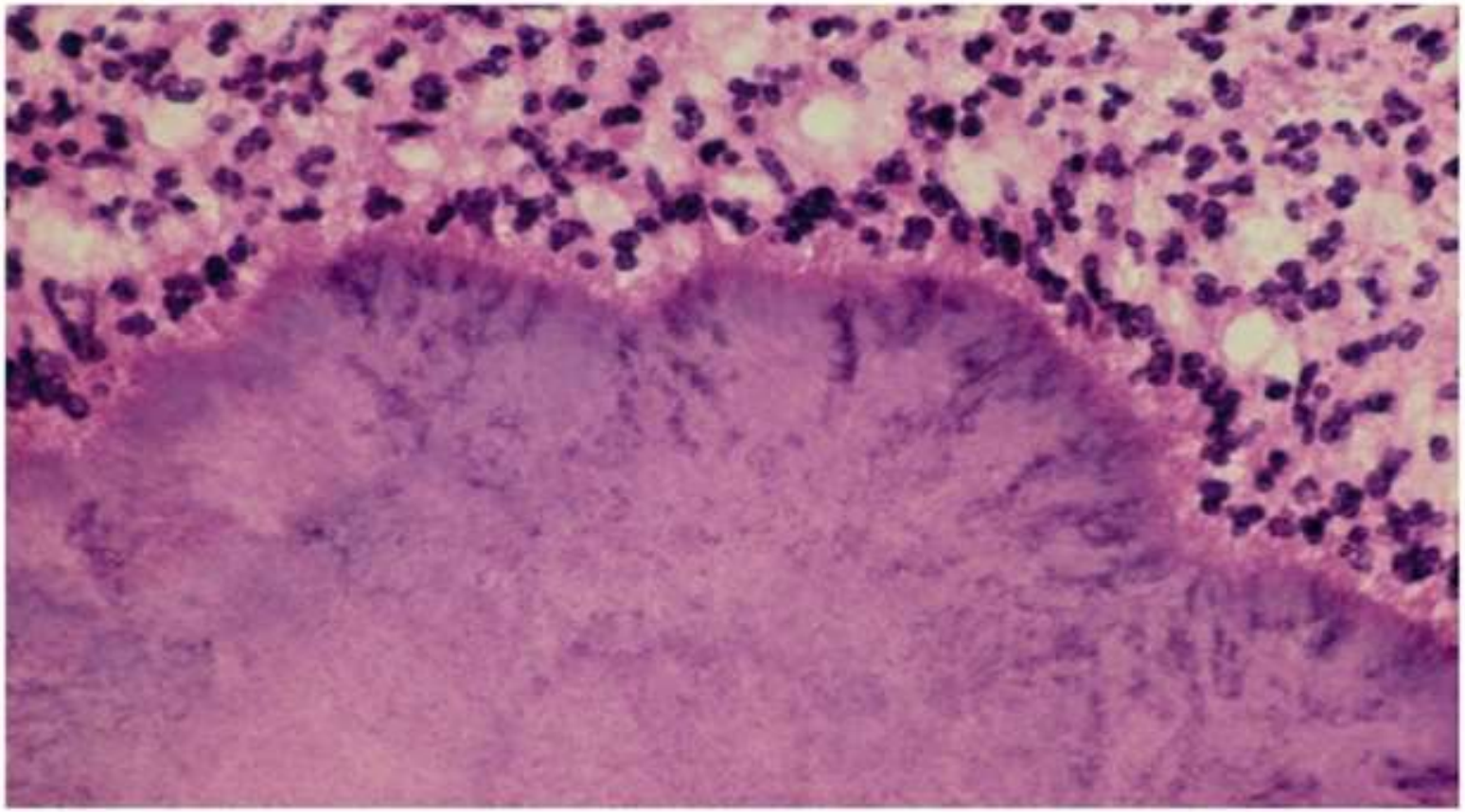

• **Fig. 5-33 Actinomycosis.** Actinomycotic colony exhibiting club-shaped filaments arranged in a radiating rosette pattern.

Fungal infections

• **Fig. 6-1 Pseudomembranous Candidiasis.** Multiple white plaques overlying erythematous mucosal change on the soft palate.

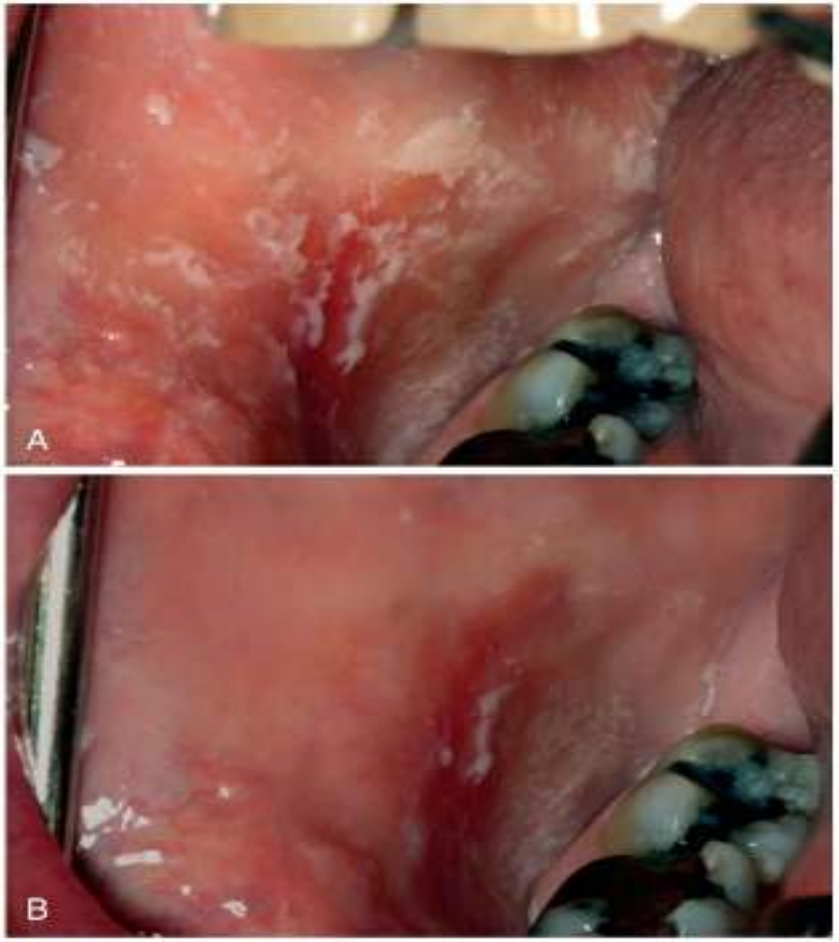

• **Fig. 6-2 Pseudomembranous Candidiasis. A,** White plaques on an erythematous base, characteristic of pseudomembranous candidiasis. **B,** Removal of several of the pseudomembranous plaques reveals a mildly erythematous mucosal surface but no evidence of bleeding.

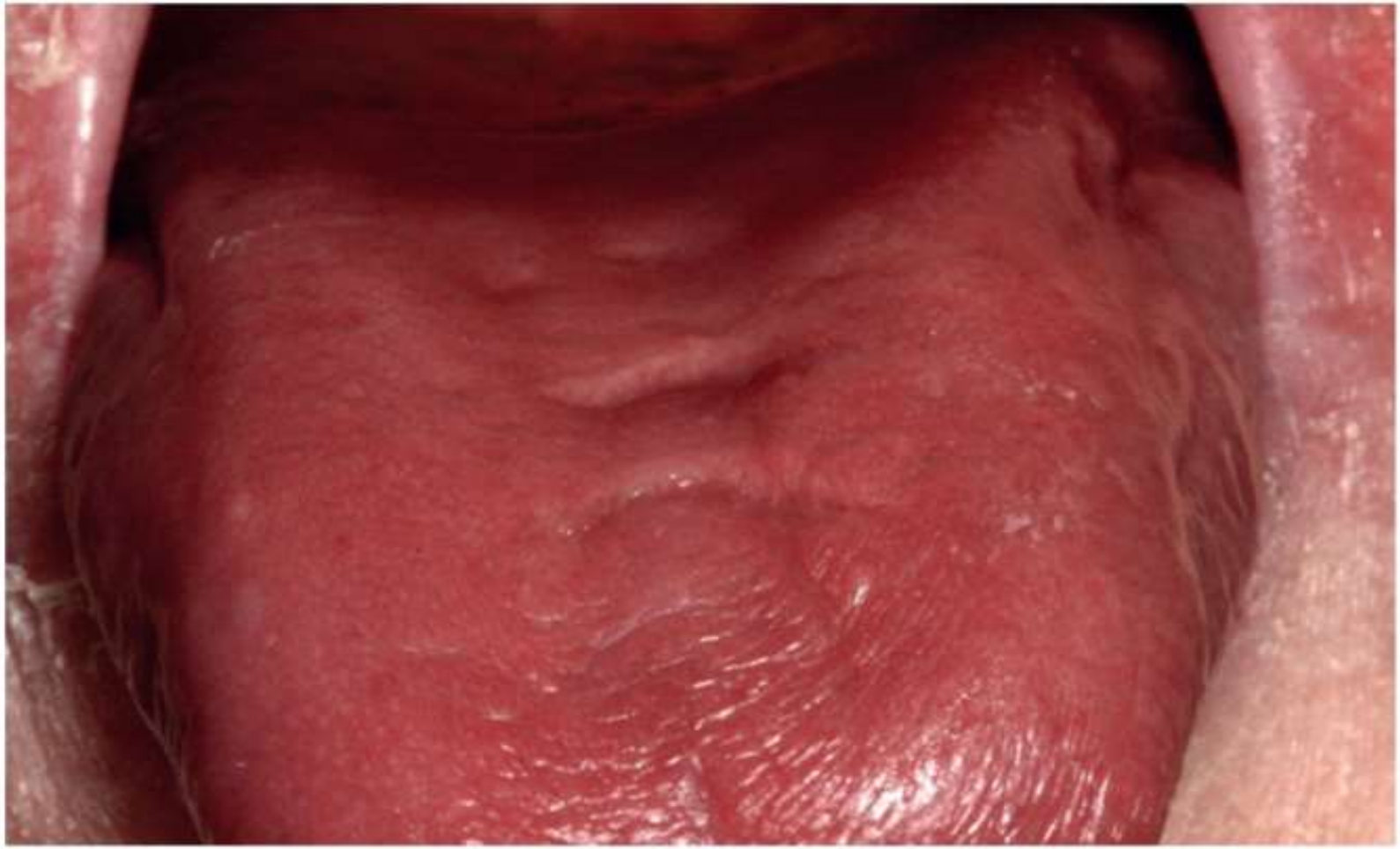

• **Fig. 6-3 Erythematous Candidiasis.** The diffuse erythema with a smooth atrophic appearance of the dorsal tongue represents erythematous candidiasis.

• **Fig. 6-4 Erythematous Candidiasis. A,** Severe presentation of central papillary atrophy. In this patient, the lesion was asymptomatic. **B,** Marked regeneration of the dorsal tongue papillae occurred 2 weeks after antifungal therapy with fluconazole.

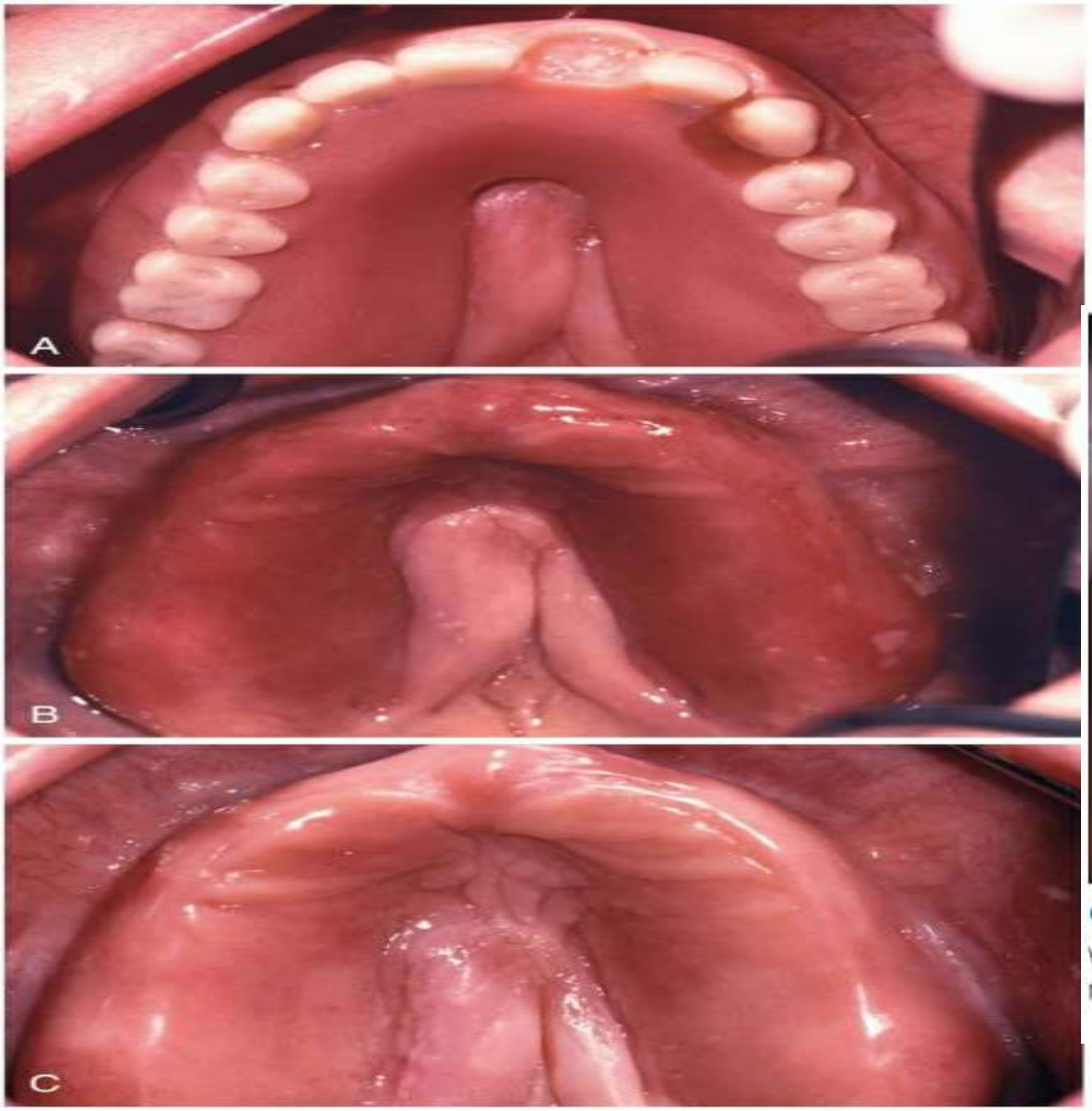

• **Fig. 6-8 Denture Stomatitis. A,** Maxillary denture with incomplete palatal vault associated with midline tissue hyperplasia. **B,** Mucositis corresponds to the outline of the prosthesis. **C,** Resolution of mucositis after antifungal therapy and appropriate denture cleansing.

• **Fig. 6-9 Denture Stomatitis.** Denture stomatitis, not associated with *Candida albicans*, confined to the denture-bearing mucosa of a maxillary partial denture framework.

• **Fig. 6-6 Angular Cheilitis.** Characteristic lesions appear as fissured, erythematous alterations of the skin at the corners of the mouth.

FIGURE 7-43

Chronic mucocutaneous candidiasis. A patient with refractory candidiasis of the oral mucous membranes **(A)**, eyelids **(B)**, and skin surrounding the nail bed **(C)**.

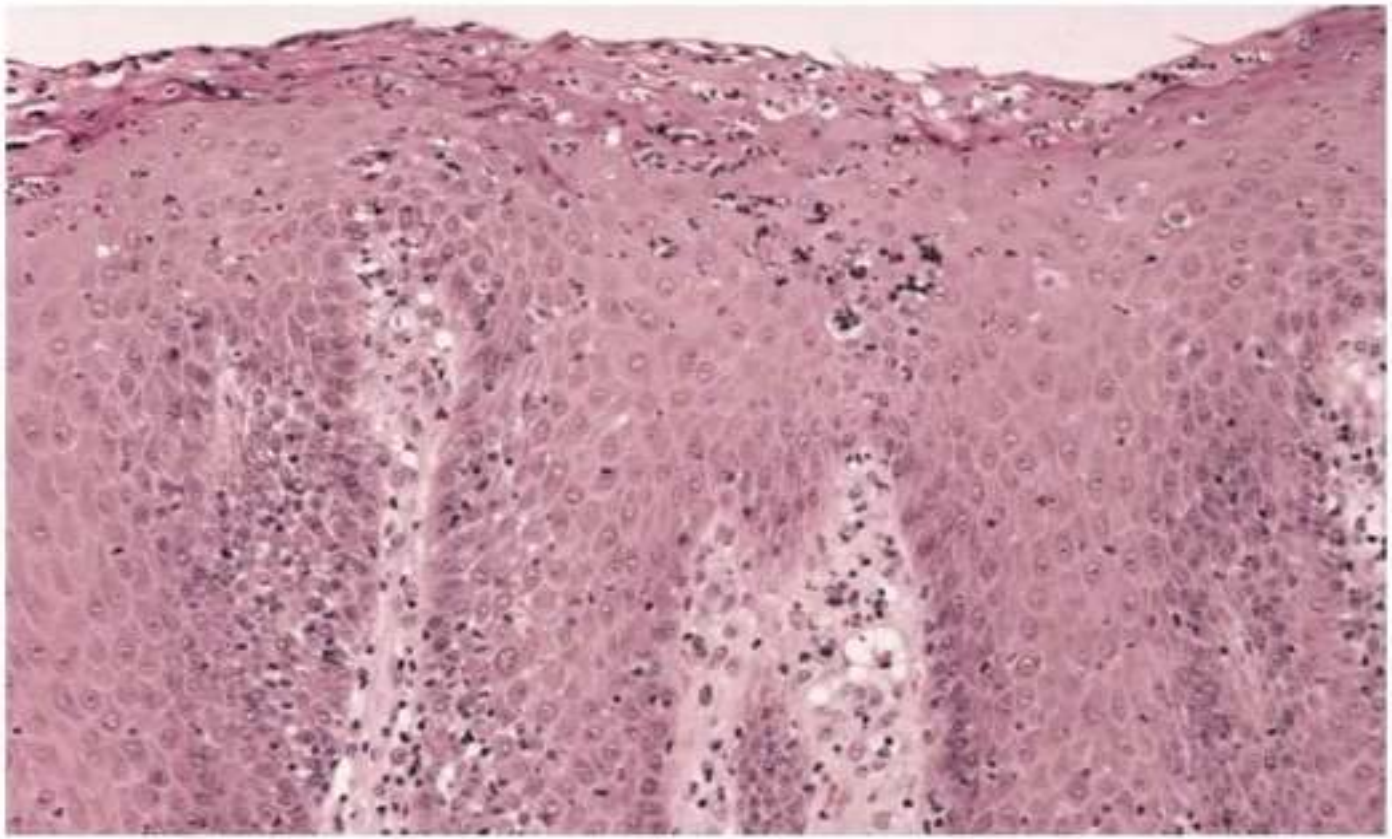

• **Fig. 6-15 Candidiasis.** This medium-power photomicrograph shows a characteristic pattern of parakeratosis, neutrophilic microabscesses, a thickened spinous layer, and chronic inflammation of the underlying connective tissue associated with long-standing candidal infection of the oral mucosa.

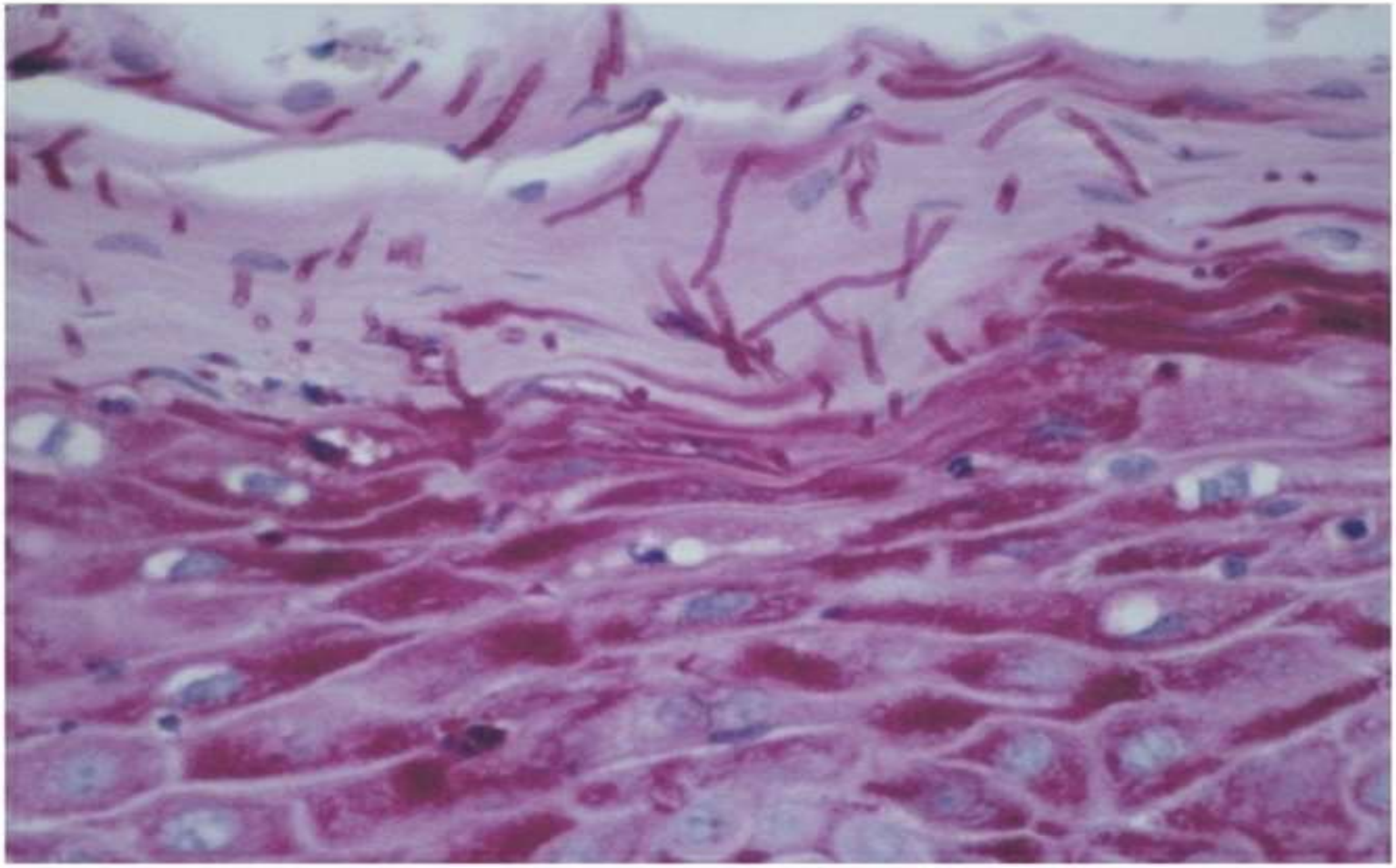

• **Fig. 6-16 Candidiasis.** This high-power photomicrograph shows the tubular hyphae of *Candida albicans* embedded in the parakeratin layer. (Periodic acid-Schiff [PAS] stain.)

Deep fungal infections

- characterized by primary involvement of the lungs. Infections may disseminate from this focus to involve other organs.

• **Fig. 6-19 Histoplasmosis.** This chronic ulceration of the ventral and lateral tongue represents an oral lesion of histoplasmosis that had disseminated from the lungs. The lesion clinically resembles carcinoma; because of this high-risk site, biopsy is mandatory.

• **Fig. 6-18 Histoplasmosis.** This ulcerated granular lesion involves the mandibular labial vestibule and is easily mistaken clinically for carcinoma. Biopsy established the diagnosis. (Courtesy of Dr. John Werther.)

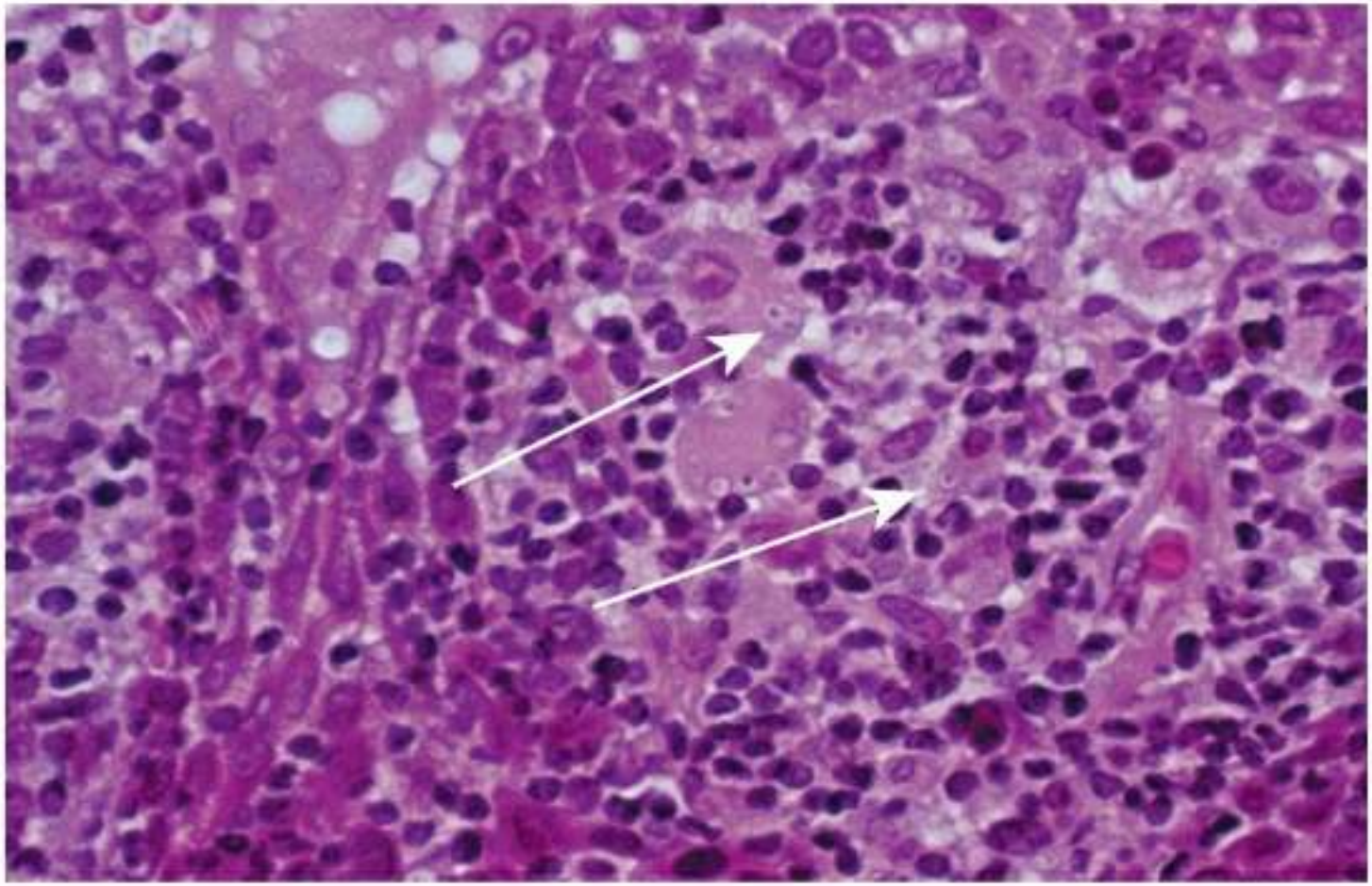

• **Fig. 6-20 Histoplasmosis.** This medium-power photomicrograph shows scattered epithelioid macrophages admixed with lymphocytes and plasma cells. Some macrophages contain organisms of *Histoplasma capsulatum (arrows)*.

Fig. 6-22 Blastomycosis. This granular erythematous plaque of ıtaneous blastomycosis has affected the facial skin. (Courtesy of Dr. illiam Welton.)

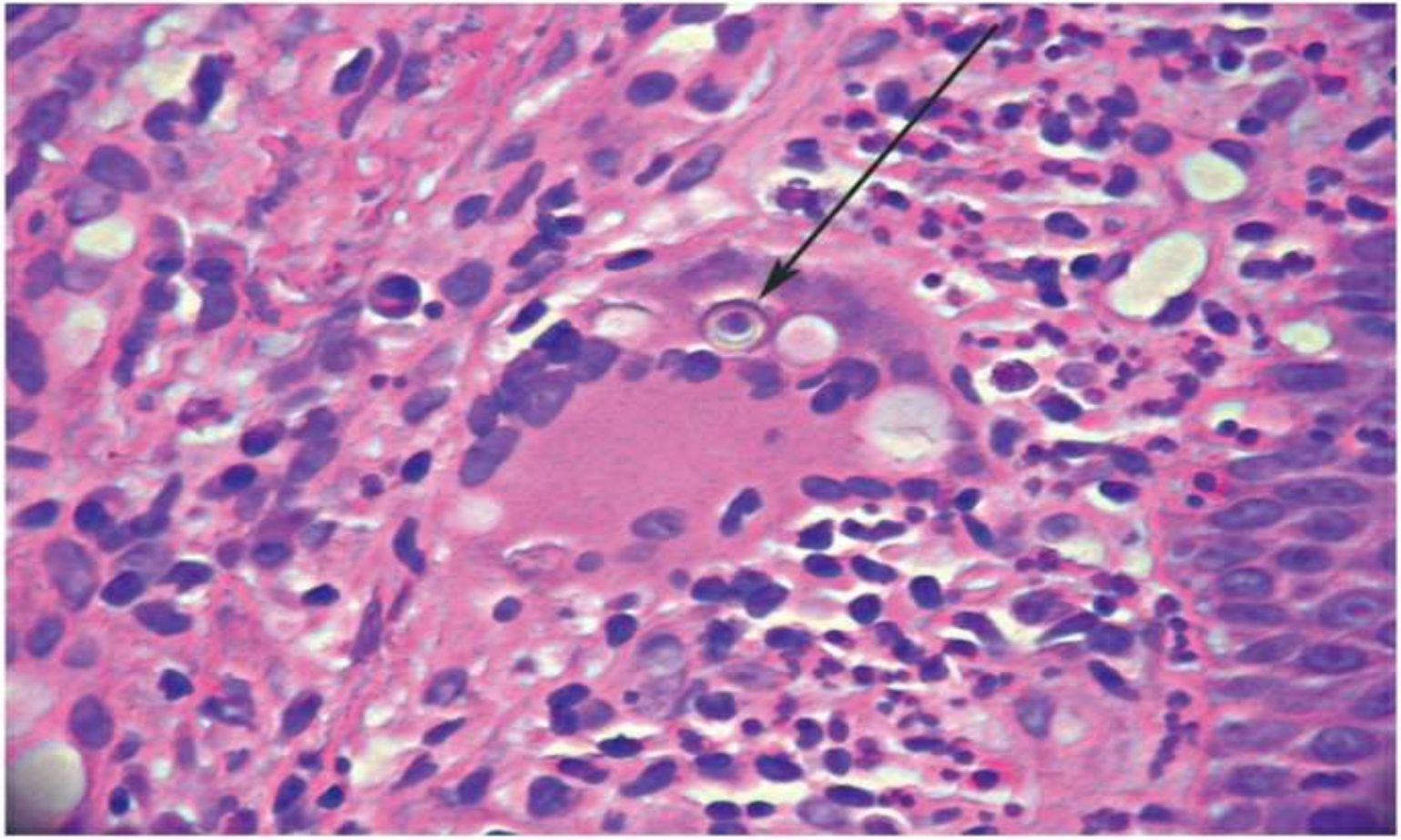

- **Fig. 6-26 Blastomycosis.** This high-power photomicrograph shows the large yeasts of *Blastomyces dermatitidis (arrow)* within a multinucleated giant cell.

• **Fig. 6-30 Cryptococcosis.** These papules of the facial skin represent disseminated cryptococcal infection in a patient infected with human immunodeficiency virus (HIV). (Courtesy of Dr. Catherine Flaitz.)

• **Fig. 7-32 HIV-associated Candidiasis.** Extensive removable white plaques of the left buccal mucosa.

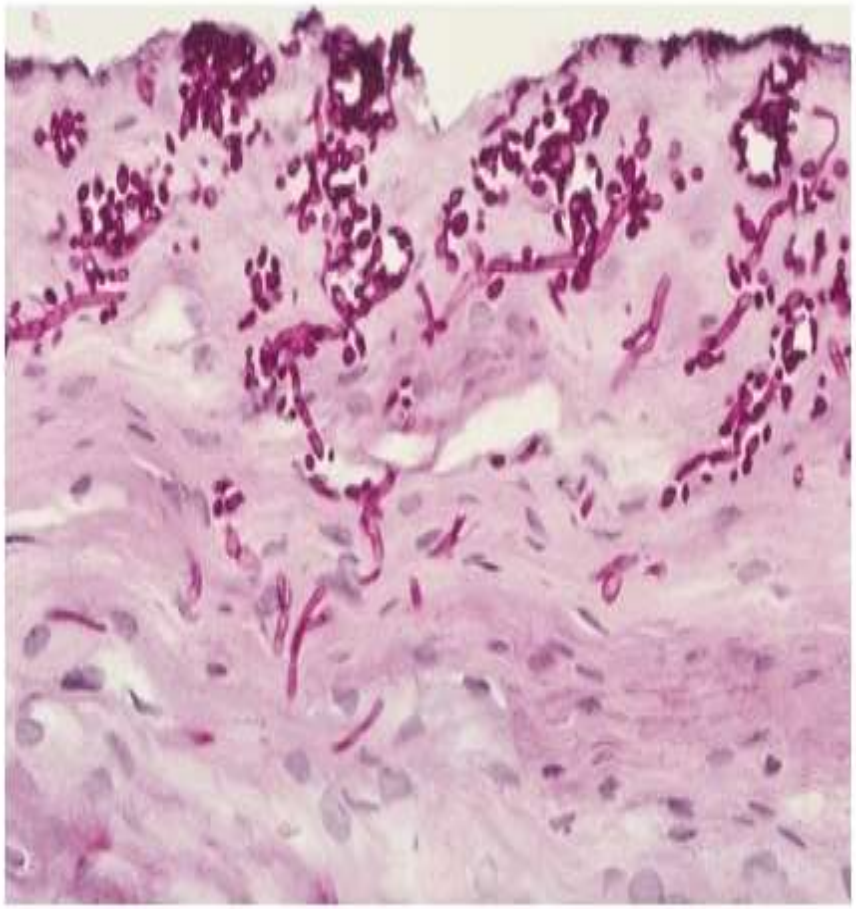

• **Fig. 7-33 HIV-associated Candidiasis.** Periodic acid-Schiff (PAS) stain of histopathologic section exhibiting numerous fungal organisms embedded in superficial keratin.

• **Fig. 7-34 HIV-associated Oral Hairy Leukoplakia (OHL).** Vertical streaks of keratin along the lateral border of the tongue.

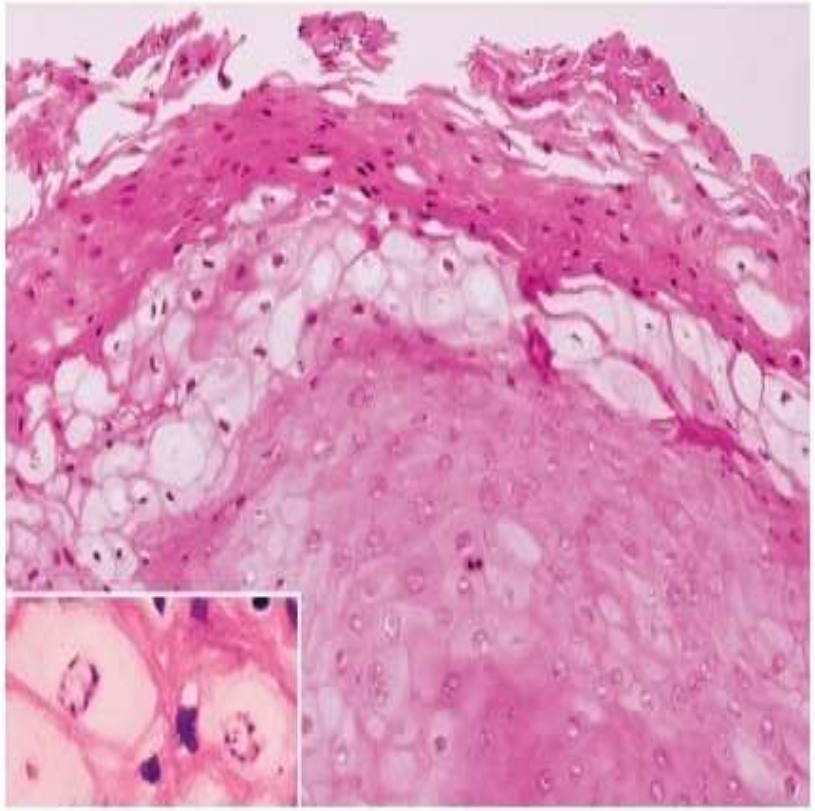

• **Fig. 7-36 HIV-associated Oral Hairy Leukoplakia (OHL).** Oral epithelium exhibiting hyperparakeratosis and layer of "balloon cells" in the upper spinous layer. *Inset* reveals high-power magnification of epithelial cells that demonstrate nuclear beading.

• **Fig. 7-46 HIV-associated Necrotizing Ulcerative Gingivitis (NUG).** Multiple punched-out interdental papillae of the mandibular gingiva. Note diffuse pseudomembranous candidiasis of the surrounding mucosa.

• **Fig. 7-47 HIV-associated Periodontitis.** Extensive loss of periodontal support without deep pocketing.

• **Fig. 7-38 HIV-associated Kaposi Sarcoma (KS).** Multiple purple macules on the right side of the face.

• **Fig. 7-40 HIV-associated Kaposi Sarcoma (KS).** Raised, dark- anterior facial gingiva.

• **Fig. 7-41 HIV-associated Kaposi Sarcoma (KS).** Diffuse, red-blue nodular enlargement of the left hard palate.

• **Fig. 7-56 HIV-associated Aphthous Ulceration.** Large superficial ulceration of the posterior soft palate.

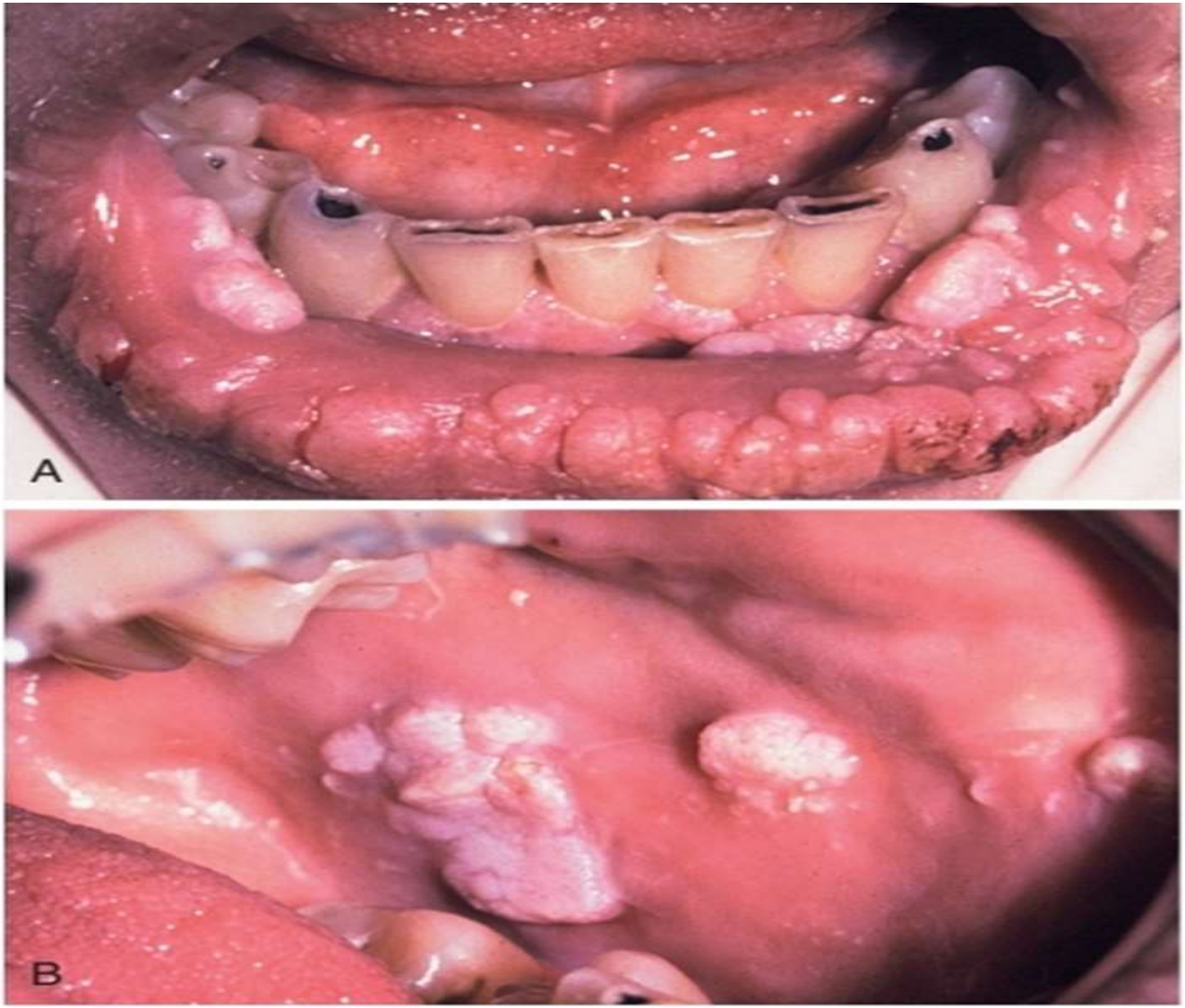

• **Fig. 7-51 HIV-associated Human Papillomavirus (HPV) Infection.** Multiple exophytic and somewhat papillary nodules of the lip, buccal mucosa, and gingiva.

• **Fig. 7-55 HIV-associated Histoplasmosis.** Indurated ulceration with a rolled border on the dorsal surface of the tongue on the right side.

• **Fig. 7-59 HIV-associated Squamous Cell Carcinoma.** Ulceration with raised, indurated borders on the lateral tongue.

Thank you